

The Successful Crown Delivery

Understanding Occlusal and
Contact Problems in Crown and Bridge

Robert R. Cowie, DDS, FAGD



QUIZ

1/2 point CDT or
RG documented
scientific credit.
See Page 44.

When I talk with laboratory owners and technicians, the most common problem they say they encounter in the laboratory is occlusal and contact problems with crowns and bridges. This appears to be a universal complaint because as many as 70 percent of the dentists I've spoken with report the same problem as their number one source of frustration with their laboratory.

If technicians and dentists can overcome even a moderate percentage of the occlusal and contact problems they encounter, the dentist client would be sufficiently pleased to start, continue or increase business with the laboratory. Eliminating occlusal problems can be an effective tool to improve the relationship between the dentist and the laboratory as well. It would lessen the problems encountered and improve the restoration.

Recently, I conducted a small study to show where the preponderance of errors come from and to give the dentist and their staff a system to evaluate where the errors are occurring and make subsequent corrections in their procedures. At the same time, if the laboratory was making errors, they would be identified and subsequent corrections made on their part.

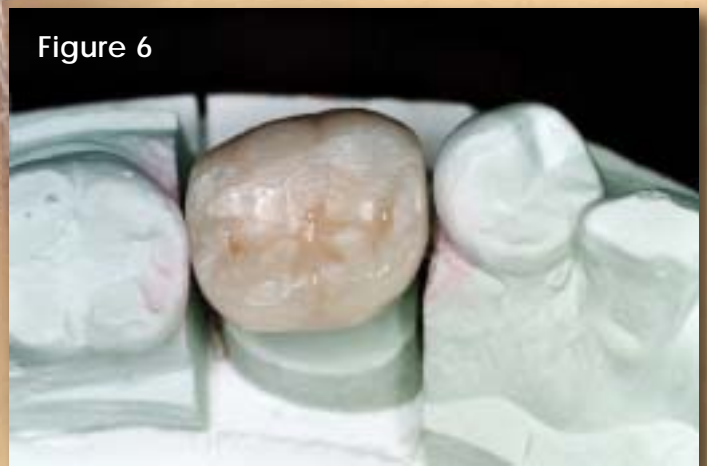
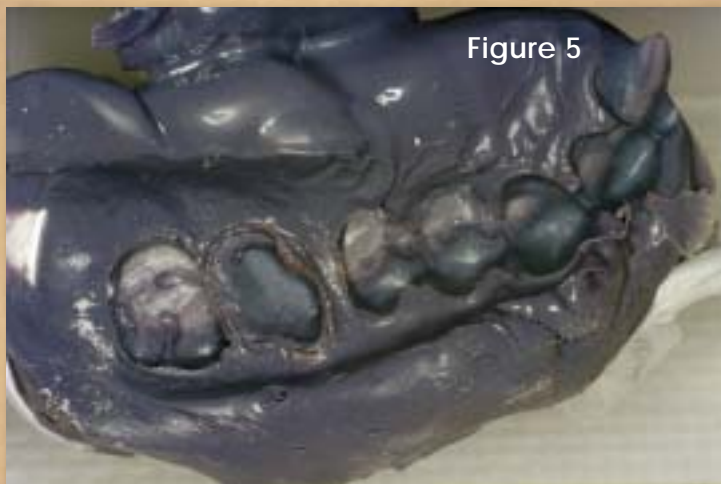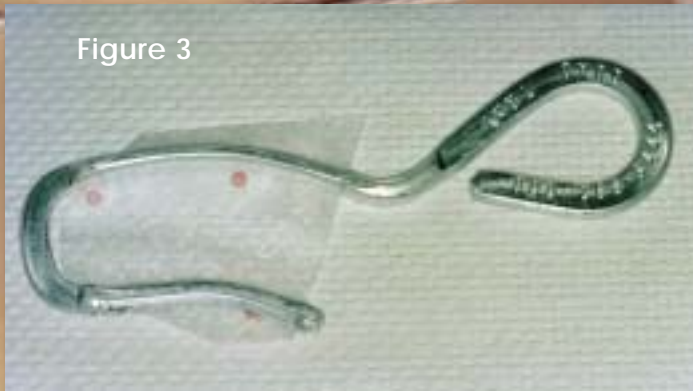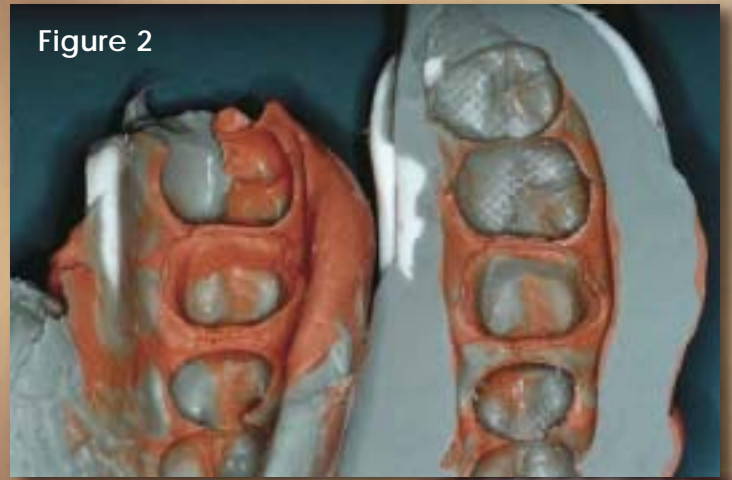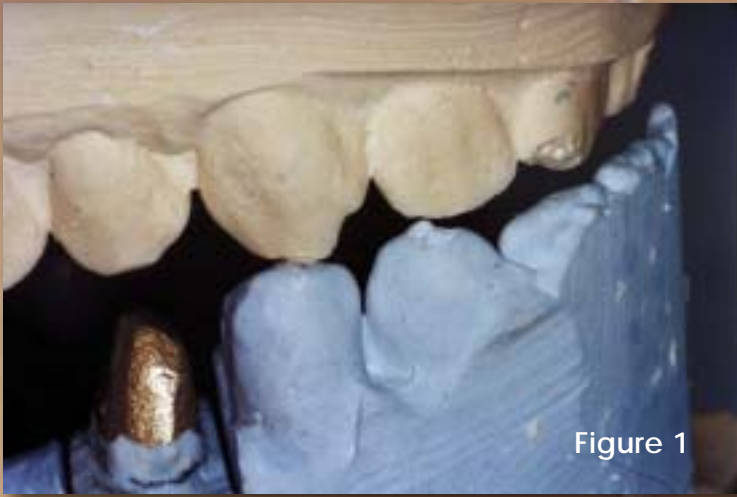As part of the study, I visited roughly 25 commercial laboratories. These visits led to my belief that the laboratory is not responsible for most of the problems encountered with high occlusion and tight/open contacts in crown and bridge restorations. This belief is the result of my observations of the laboratory cases, as well as conversation with dentists. Most dentists, by my estimates about 95 percent, do not take the post-adjusted crown back to the model. If the crown fits the model and not the mouth, either the model is wrong, the mouth has changed or the crown is not seating completely in the mouth.

With the aid and cooperation of 10 dentists and 10 commercial laboratories, I collected data and photographs of 30 cases (three cases from each dentist) to use for documentation. National Dentex Corp. agreed to assist with the study. National Dentex selected the laboratories to be used in this study and randomly assigned the laboratories to the dentists, who had no prior relationship with the laboratory.

Primarily high occlusion and contact problems would be the focus – not dentists who were having difficulty with marginal impression accuracy. Each dentist was given total anonymity and, as an incentive to participate, the laboratory fees for the single unit crowns would be waived. The only financial implication for the dentist would be the cost of their time and additional impression materials.

The dentists prepared the crowns and took impressions in their usual fashion. The supposition was that the majority of these would be done with a dual arch quadrant impression system. The dentists took a second impression using a full arch stock tray, while providing the necessary opposing model and bite registration.

The laboratory completed the restorations – one on the quadrant model and one on the full arch model. Both were sent to the dentist for the seating appointment. The crowns were photographed and evaluated on the models as they were returned from the laboratory using an 8mm shimstock foil to evaluate occlusion on the model. Once both crowns were adjusted to the patient's mouth, the crowns were taken back to their respective models. Photo documentation of the adjusted crown and the temporary restoration on the model were completed. The dentists evaluated the time variation needed for adjustments.



Results and Solutions

Dentists found that in 28 of the 30 restorations, it took less time to seat the full arch impression crown than the dual arch quadrant impression crown. One dentist saw no difference and one dentist said it took longer with the full arch impression. As a side note, the tray impression material for that restoration did not adequately bond to the syringable impression material causing the crown to be completely rejected by the dentist as unacceptable in fit.

I frequently observed a number of errors with the use of dual arch quadrant trays. The tray was poorly positioned in most cases. **Figure 1** shows that the bite recorded is not correct because the teeth are not in occlusion and wear facets don't line up, yet it has an inadequate number of teeth to hand remount because only a quadrant impression was taken. Impingement of both hard and soft tissue into the tray caused distortion that was documented in this study to cause problems with occlusion, fit and contact. **Figure 2** shows that in the left impression, the tray was not positioned far enough posteriorly to allow the patient to reach maximum intercuspation and that in the right impression the tray was not positioned in the correct buccal lingual position to prevent occlusal forces to distort the tray.

No dentist was observed utilizing a metal quadrant tray (Quad Tray, Clinician's Choice), although it is frequently mentioned in lectures that a metal tray will not, and in fact cannot, distort from occlusal forces (**Figure 3**). A variety of impression materials were used, some which are not satisfactorily rated to be stiff enough to be used in a sideless tray.

In other cases, there were an inadequate number of teeth incorporated into the impression to provide the laboratory with enough information to fabricate a crown correctly. **Figure 4** shows a frequently observed error — the failure to include the cuspids, which is necessary to determine the inclines of the cusp tips and fossa. **Figure 5** fulfills all of the perimeters of a good dual arch quadrant impression: metal tray, cor-

rect positioning, maximum intercuspation and firm non-distorting impression material.

Of the 60 crowns evaluated, only two crowns required absolutely no adjustment in the mouth. Adjustment in the mouth included even minimal adjustment such as removal of glaze with an abrasive rubber wheel. After adjustment in the mouth, only one crown was observed to hold the shimstock foil on the model.

It appears unreasonable to expect a crown not to require any adjustment unless the dentist is willing to accept crowns that are frequently out of occlusion and/or contact when seated. Knowing the sensitivity of the masticatory system and the chance of introducing TMD symptoms because of the lack of occlusal precision, ordering crowns to be made out of occlusion in order to expedite the crown seat appointment would be considered below the level of standard in most dental circles.

Less than ideal temporary restorations were observed in 75 percent of those evaluated on the master models. **Figure 6** shows how the temporary crown removed from the mouth appears on the working model. The mesial contact is open. Extensive contact adjustment was required to seat the crown. Please note that not all of the dentists were willing to have their temporary restorations submitted for photo documentation.

A temporary restoration that is initially placed out of occlusion or contact cannot adequately stabilize the mouth between the preparation and seat appointments. A temporary crown placed on the working model as seen in **Figure 7** indicates that the prepared tooth and the opposing tooth were not in occlusion, allowing for supraeruption to occur between prep and seat appointments necessitating extensive occlusal adjustment prior to seat.

Interestingly, there appeared to be no correlation between prep and seat appointments and the amount of adjustment needed. The hypothesis is that an unstabilized tooth reaches a new equilibrium relatively quickly.

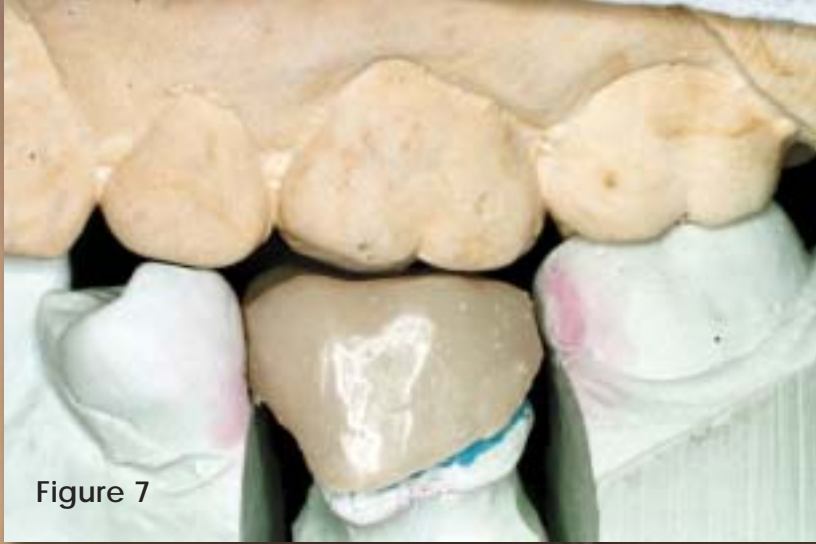

Figure 7

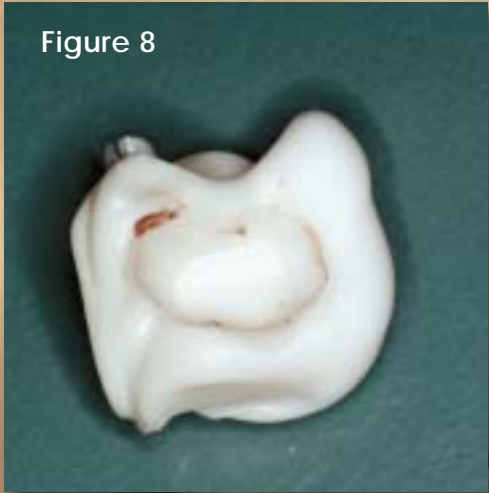

Figure 8

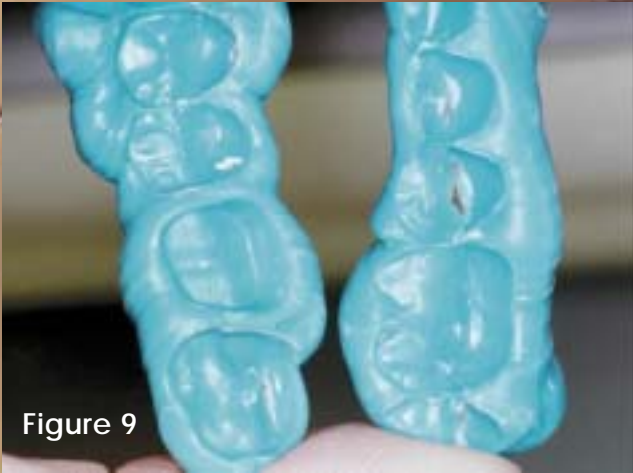

Figure 9

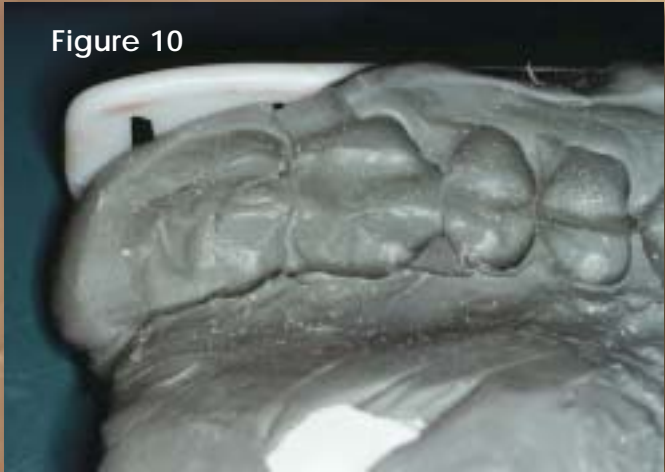

Figure 10



Figure 11

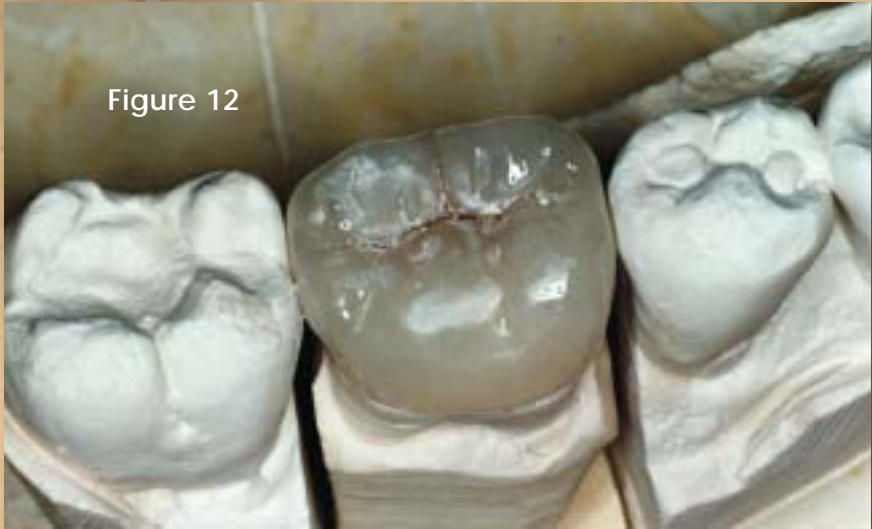

Figure 12

Not one dentist or assistant was observed to have checked the crown to determine if it was completely seated on the tooth. Anonymous surveys during continuing education seminars of about 1,000 dentists indicate that only about 5 percent are familiar with and use a thin silicone based fit checking material (Fit Checker, GC America) to check the accuracy of a crown fit in the mouth.

Not one dentist or assistant was observed to critically assess the crown on the model after the laboratory returned it to make sure that the crown fit the model before they tried it in the patient. After adjustment, not one dentist or assistant was observed to go back to the original working model to check the crown after adjustment.

It is quite apparent after presenting seminars to hundreds of dentists over the last three years in 27 states that there is a widespread loss of the concept that if the crown fits the model and not the mouth, the laboratory cannot be held at fault. The technician's job is to make a precision restoration that fits precisely to the model. As simple as this concept seems, it is lost in reality in the hectic and frantic pace of most dental offices. It is easier to pick up the phone and blame problems on someone else than it is to analyze the problem and thoughtfully determine what could have gone wrong and who could have done what better.

Poor bite registration techniques were observed to have contributed to problems in four of the full arch cases and seven of the dual arch quadrant cases. Most of these occurred in the dual arch quadrant trays. Frequently, the patient never reached maximum intercuspation. This could be a result of one or more of several things:

- Incorrect positioning of the tray.
- Inadequate visualization of the affected area due to the large bulk of material that the tray holds.
- Lack of the patient's ability to find maximum intercuspation.

In the full arch cases, frequently the dentist or assistant placed the bite registration material on the entire arch instead of just over the prepared tooth.

Figure 8 illustrates the correct placement of the bite registration material to facilitate the patient reaching maximum intercuspation. Placing the material on the entire arch can cause the patient in some cases to again fail to be able to find their maximum intercuspation (**Figure 9**).

Four full arch cases showed a need for improved opposing arch impressions. Errors occurred in the opposing tooth that altered in some cases the occlusal contact of the crown being fabricated. In some cases, the actual mounting was wrong because the terminal tooth in the opposing impression was distorted. **Figure 10** shows the distorted terminal molar in a polyvinyl siloxine opposing impression. The resulting crown seen in **Figure 11** was very high due to the mounting error in the opposing tooth. Dentists and their staffs have to be cautioned to scrutinize both the working arch impression and the opposing arch impression.

Four of the 10 participating dentists voluntarily used a polyvinyl siloxine impression material designed as an alginate substitute for the opposing arch. No determination in this study was made as to how much effect the added accuracy contributed to occlusal accuracy with single units. Logically, it would seem to have an increasing effect with regards to how many units are being fabricated.

Five cases showed that the errors in occlusion could be contributed to the fact that the models were not correctly prepared by removing air bubbles, blebs and other surface artifacts prior to mounting. This, of course, resulted in the models being mounted high to begin with and the resulting crowns being equally high. **Figure 12** shows a very natural looking occlusal table with no other instruction from the dentist but "make crown, D-3." Unfortunately, the adjustment required to compensate for the bubbles on the adjacent bicuspid resulted in a complete decimation of the technician's skillful labors.

Poorly prepared occlusal surfaces were seen in both the working model and in the opposing model. Laboratories often delegate model work to the least experienced employee. Adequate training, supervision

and subsequent quality control procedures need to be in place to insure the laboratory avoids this easily prevented error.

A few cases were returned with models broken or removed from the quadrant disposable articulator. Care needs to be taken in packing and shipping so that the dentist and staff can adequately evaluate the occlusion and contact on the model before the patient arrives. This is the dentist's assurance that the laboratory has done its job — fabricating a crown that precisely fits the model.

In some cases, full arch models were not equilibrated to remove occlusal prematurities in stone. Twelve of 30 cases showed rocking in the hand articulated models.

Both dentist and laboratory need to be reminded upon occasion that they work with two very different systems. As a dentist, my work is primarily done on a patient in a biological system, while laboratory technicians work primarily with a stone model system that never exhibits a biological adaptation. Specifically, the patient with an occlusal prematurity has a biological component that allows the tooth to move slightly within the periodontal ligament space, either laterally or apically. When a full arch impression (or a dual arch impression that does not reach maximum intercuspation) is taken, the tooth in prematurity does not move. When the impression is poured in stone, it now serves as an interference to mounting.

Most dentists doing single tooth dentistry are not equilibrating their patients prior to doing any restorative dentistry. To overcome this, full arch models can

be hand articulated and any movement that prohibits precise interdigitation of the models can be considered a sign of a prematurity. The models can be equilibrated in the stone to accommodate for the tooth movement that happens in the biological model.

Although this was a small study in number, is not statistically valid and was not conducted as a double blind study, the results are nonetheless conclusive to me as a practicing clinician. Inappropriate dual arch quadrant impressions contributed to the majority of errors that occurred. Dentists have either never been taught their correct use or have drifted away from correct usage. Unless well understood this can become a major obstacle to developing the strong dentist-laboratory relationship that is desired. **JDT**

The author wishes to thank the Mr. David Brown and the National Dentex Corporation for support in this study.

About the Author:



Cowie is a graduate of Northwestern University Dental School and has a private practice in Jacksonville, Fla. He is a member of numerous dental organizations, as well as a Fellow in the AGD and American College of Dentists.

QUIZ: Receive 1/2 point CDT or RG documented scientific credit for reading this article and passing the quiz! To get your credit, complete the quiz located on JDT Unbound at www.nadl.org/jdtunbound using the CDT Quizzes link, or call the NBC Fax-on-Demand at (877) 355-8029, Press 1 for NBC documents, and enter document number 48 to have the quiz sent to your fax machine. Once completed, fax to NBC at (850) 222-0053. This quiz is provided to test the technician's comprehension of the article's content and does not necessarily serve as an endorsement of the content by NADL or NBC.

NADL
National Association of
Dental Laboratories